

## Comparative Study between IMF and Pure Conservation in Management of Condylar Head Fracture in Children

Majed Alharbi<sup>1</sup> and Hamada Mahran<sup>2\*</sup>

<sup>1</sup>Resident of oral and maxillofacial surgery, ministry of health, Saudia Arabia

<sup>2</sup>Lecturer of maxillofacial and plastic surgery, general surgery department, faculty of medicine, Assiut university, Egypt

### \*Corresponding author

Dr. Hamada Mahran, Lecturer of maxillofacial & Plastic Surgery faculty of medicine, Assiut University, Egypt, E-mail: dr.h.mahran@gmail.com

Submitted: 05 Mar 2018; Accepted: 29 Mar 2018; Published: 12 Apr 2018

### Abstract

**Background:** The purpose of the present study was to compare IMF and pure conservation in management of condylar head fracture in children treated at the Department of Maxillofacial Surgery, Faculty of Medicine, Assiut University, Egypt, between 2011G - 2016G.

**Methods:** Twenty four patients with condylar head fractures were included in this study, 14 males and 10 females ranging in ages from 5 – 15 years. They were divided into two equal groups. In group 1, twelve patients were treated by closed reduction for 2-3 weeks followed by physiotherapy, while group 2 patients were managed by pure conservation only for the same period. Outcome results on clinical and radiological parameters were evaluated during the follow up period.

**Results:** In group 1, the maximum mouth opening after 2 months was ranged from 28-36 mm (average 32mm), while signs of development of ankylosis were reported in 3 patients. In group 2, the maximum interincisal opening was ranged from 28-37 mm (average 32.5mm) with absence of ankylosis. Pain in TMJ was noted in 3 cases of bilateral condylar head fractures of this group, but subsided gradually on the follow up.

**Conclusions:** This study concluded that treatment of patients by closed reduction give satisfactory clinical results, though the condyle is not anatomically normal in radiographs. Whereas management of patients by pure conservation only without any surgical intervention showed excellent results clinically as well as radiographically. Perhaps a study conducted on larger number of patients with longer post operative follow up will throw more light on this subject.

### Introduction

The mandible, or the lower jaw bone, is one of the twenty-two bones that make up the skull and the only one of those bones that is not fused to its neighbors. It is the strongest and most massive bone in the face. The mandible plays a vital role in many common tasks, including chewing, speech and facial expression [1-3]. Given its prominent anatomic location, mandibular bone fractures (57%) is the tenth most common fracture in the human body and second most of the facial bones next only to nasal bones [4-7]. Mandibular fractures occur most commonly among males in their 30s [4,5].

Among the mandibular bone fractures, condylar region is the most frequent site ranges from 20% to 35% of all cases [8-12]. The condyle represents a structural weak point in the mandibular skeleton because of its shape and the slenderness of its neck and sometimes its being fractured avoids more serious consequences such as fractures of the base of the skull which can traumatically interrupt propulsive strength [9,10]. Condylar fractures are usually resulted from a direct

blow to the chin or to the lateral side of the jaw caused by Road traffic accidents, violence, accidental falls and sporting injuries [13-19].

Mandibular condylar fractures are classified according to the anatomic location into intracapsular and extracapsular and degree of dislocation of the articular head [20-25]. Concerning the management of mandibular condyle fracture, there are different methods of condylar fractures treatment with a great deal of discussion and controversy due to differences in outcome results of various retrospective and prospective studies [26-35]. For each type of condylar fractures, the treatment procedures must be chosen taking into consideration the presence of teeth, level of the fracture height, patients adaptation, patients masticatory system, disturbance of occlusal function, deviation of the mandible, internal derangements of the TMJ and ankylosis of the joint [36-40].

There are two principal therapeutic approaches to condylar fractures: Open reduction or surgical treatment and closed reduction or non

surgical (functional) treatment [41-46]. In this regard, many studies covering the treatment modalities of condylar fracture were reported [47-53]. Almost without exception, published studies described acceptable results with either of the two treatment options. Some stated a preference for closed reduction, owing to significant disadvantages of surgery, like scarring, postoperative pain or facial nerve paralysis [54-59]. Others, on the contrary, described a preference for open reduction and internal fixation, for better anatomical reduction, range of motion and/or functional outcomes [49-58]. Consistent with the forementioned data, the present study was designed to investigate and compare the clinical and radiological outcomes between maxillomandibular fixation and pure conservation in management of mandibular condylar head fractures in children, based on the current literature.

### Materials and Methods

This retrospective study was conducted with the patients who had been referred for treatment of mandibular condyle fractures of head and neck types at the Department of Maxillofacial Surgery, Faculty of Medicine, Assiut University, Egypt, during the period between 2011G - 2016G. Twenty four patients with already diagnosed isolated mandibular condylar head fractures were included in this study, 14 males and 10 females ranging in ages from 5 – 15 years with a median of 10 years. The locations of condylar head injuries were as followed: 12 cases involved bilateral condyle, 6 cases concerned right condyle and 6 cases occupied left condyle. This work was conducted after obtaining approval from the university ethical committee and informed consent was obtained from the patient after thoroughly explaining the advantages and disadvantages of nonsurgical and surgical treatment options roentgenograms i.e. OPG (Orthopantomogram) and computed tomography scanning (Figure 1 & 2). Exclusion criteria were a history of medical problems or psychiatric disorders or mental retardation and impairments in mandibular function or pain in the mandibular locomotor system before fracturing the mandibular condyle. The 24 patients were divided into two equal groups, each group includes 12 patients (7 males and 5 females). In group 1, 12 patients (7 males and 5 females) had undergone non surgical management of mandibular condylar fractures which included closed reduction with maxillomandibular fixation ranging from 2-3 weeks followed by physiotherapy.

The other 12 patients (7 males and 5 females) of group 2 were undergone pure conservation only without any surgical intervention for the same period (2-3 weeks). Post operative follow up period for both groups was ranged from 3-12 months. Various complications associated with nonsurgical and surgical treatment of condyle fractures were assessed with respect to the following parameters: Mouth opening, deviation of the mandible, pain in temporomandibular joint, malocclusion and development of ankylosis. All clinical data of the studied patients are summarized in table 1.

Finally, the displayed data were statistically analyzed in each group and comparison of surgical and nonsurgical treatment of condylar fracture with respect to postoperative outcome were performed using the Chi - square test to conclude the most significant method for management of mandibular condylar head fractures.

### Results

Treatment of mandibular condylar head fracture was performed according to the standard procedures of the Department of Maxillofacial Surgery of the Faculty of Medicine, Assiut University, Egypt. In this present study, 24 patients with isolated mandibular condylar head fractures were included. Out of 24 patients, 10 (41.6%) were females and 14 (58%) were males. Fall on the ground was the most common cause in that age group (63%), Road traffic accidents were the second cause of trauma in (17%), followed by Assault cases (8.3%), and other injuries in (12%) of the cases (Figure 5).

In this study, the 24 patients (100%) were equally divided into two groups and the isolated condylar head fractures of different sides were as followed: Bilateral condylar head fracture were involved in 12 cases (50%), right condylar fracture were involved in 6 cases (25%) and left condylar fracture were involved in 6 cases (25%). Out of 24 patients 12 patients (50%) (Group 1) were treated by closed reduction with maxillomandibular fixation ranging from 2-3 weeks followed by physiotherapy. The other 12 patients (50%) (Group 2) were undergone pure conservation only without any surgical intervention for the same period.

Post operative follow up period for both groups was ranged from 3-12 months. Initially, neither group had any patients with post-treatment malocclusion or permanent nerve injury. In group 1 or in closed reduction group, the maximum interincisal or mouth opening after 2 months was ranged from 28-36 mm (average 32mm), while development of ankylosis after 2 months were reported in 3 patients out of 12 patients. In group 2, the maximum mouth opening after 2 months was ranged from 28-37 mm (average 32.5mm). The most interesting finding of group 2 was absence of development of ankylosis after 2 months. Only pain in TMJ was noted in 3 cases (12.5%) of bilateral condylar head fractures of group 2 which got subsided gradually on follow up. None of the patients in both groups had malocclusion or facial nerve palsy. The results of group 1 and group 2 are summarized in table 2.

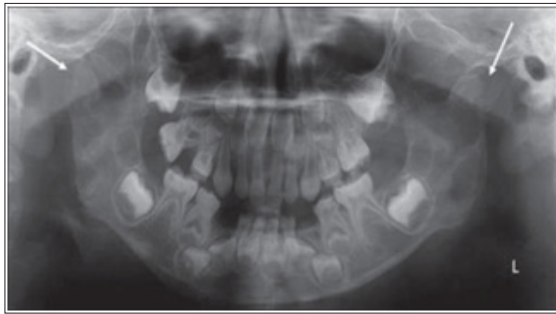There was a statistically significant difference in the range of maximum mouth opening in both groups after 3-12 months of post operative follow up period. Since the maximum mouth opening in group 1 was ranged from 28-36 mm (average 32mm), while in group 2 it was ranged from 28-37 mm (average 32.5mm). There was also a statistically significant difference in the development of ankylosis in both groups that was only reported in 3 patients out of 12 patients of group 1. Similarly, pain was significantly reported in 3 patients of group 2.

**Table 1: Clinical data of studied patients**

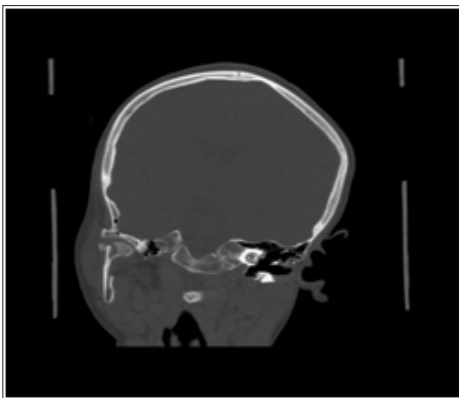
Parameter	Group 1	Group 2
Total number of patients.	12	12
Gender (female/male).	5 / 7	5 / 7
Age at injury (years).	5 – 15 years	5 – 15 years
Side of condylar fracture.		
• Right	3	3
• Left	3	3
• Bilateral	6	6

**Table 2: Results**

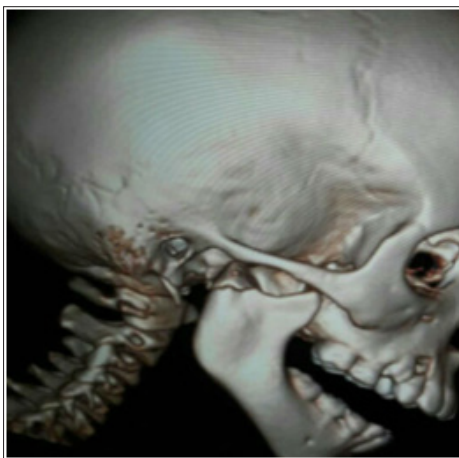	GROUP I	GROUP II
TREATMENT PLAN	IMF for 2-3 weeks	No surgical intervention
MOUTH OPENING (mm)	28-36 (32mm average)	28-37(32.5mm average)
ANKYLOSIS DEVELOPMENT	3/12	0/12
TMJ PAIN	0/12	3/12
MALOCCLUSION	0/12	0/12



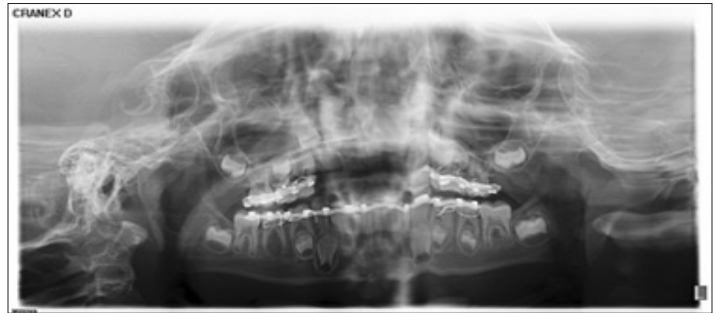**Figure 1:** Preoperative OPG showing bilateral condylar head fracture



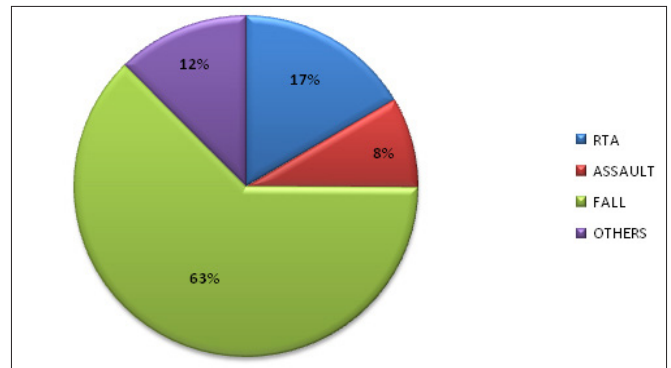
**Figure 2:** Preoperative CTSCAN showing fractured right condylar head.



**Figure 3:** Preoperative 3D showing fractured right condylar neck.



**Figure 4:** Postoperative OPG showing upper and lower arch bar



**Figure 5:** Causes of condylar head fracture

**Discussion**

In the International Literature, fractures of the mandible that involve the condyle ranges from 20% to 35% [8-12]. Injury to the mandibular condyle deserves special consideration apart from the rest of the mandible because of its anatomical differences and healing potential [9,10]. Up to the present, numerous therapeutic techniques have been used for management of mandibular condylar fractures with many arguments in favor of one treatment or a specific type of treatment based not only on personal experience, preference of the clinic or the tradition in the country, but also founded on results of retrospective studies or small prospective studies [8-11].

In the present study, the therapeutic approaches of maxillomandibular fixation and pure conservation for management of mandibular condylar head fracture in children were investigated and compared clinically and radiologically. In group 1 or closed reduction group, the maximum interincisal or mouth opening after 2 months was ranged from 28-36 mm (average 32 mm), while in group 2 or pure conservation group, the maximum mouth opening after 2 months was ranged from 28-37 mm (average 32.5mm). This finding observed reduced mouth opening in closed reduction group 1 more than that in pure conservation group 2 as evidenced clinically and radiographically. Based on the previous result, it has been revealed that pure conservation approach used in group 2 provides safer and better reduction of mandibular condylar head fracture in children and this finding correlates with the study [59-62].

This result also showed statistically significant difference in maximal mouth opening between both groups, since group 2 exhibits good mouth opening post operatively when compared to closed group 1, which also correlates with the study of Eckelt et al. [63]. In contrary to Ragupathy K., who studied outcomes of surgical versus nonsurgical treatment of mandibular condyle fractures and concluded



that nonsurgical treatment gives satisfactory clinical results, though the condyle is not anatomically normal in radiographs, whereas surgical treatment provided more accurate results clinically as well as radiographically [64].

Concerning the development of ankylosis after 2 months in 3 patients out of 12 patients of group 1 that treated by closed reduction with maxillomandibular fixation ranging from 2-3 weeks followed by physiotherapy was attributed to less physiotherapy and relatively reduced vertical ramus height in these patient more than that in other patient of the same group. This finding correlates with the study of Ellis et al., who provided the most detailed and thorough comparison of the outcomes of the closed and open approaches to mandibular fractures in a series of 9 publications [65]. They realized that the closed approach is associated with numerous problems. These include chronic pain, ankylosis, malocclusion, asymmetry, limited mobility and gross radiographic abnormalities. In contrast to Handschel J et al., who compared the 1 to 5-year postoperative findings of 20 patients treated with ORIF to 14 who were managed conservatively [66]. The conservative group was treated with maxillomandibular fixation for 2 weeks and then postoperative physiotherapy. The ORIF group was managed with wire or rigid osteosynthesis. They found that deviation on opening occurred in 64% of patients treated conservatively compared with 10% managed with ORIF.

Noteworthy, Haug et al. 5 reported the long-term postoperative results of 10 patients treated with closed reduction and 10 patients by ORIF [67]. There were no statistically significant differences in malocclusion found between the ORIF and closed reduction. Satisfactory results do not always require exact anatomical repositioning. Even when impaired growth of the mandibular ramus on the fractured side is apparent, good aesthetic and functional results are possible. Pain at TMJ was noted in 3 cases (12.5%) of bilateral condylar head fractures of group 2 which got subsided gradually on follow up. This findings correlates with the observation by Worsae et al. [68]. Finally, there no severe clinical complications in either treatment group.

Based on the above findings this study concludes that patients treated by closed reduction give reasonably good clinical results, though the condyle is not anatomically normal in radiographs. Whereas patients treated by pure conservation only without any surgical intervention show excellent results clinically as well as radiographically. This study yields functional result which were clearly in favor of pure conservation only open condylar head fractures in children. . Perhaps a study conducted on larger number of patients with longer post operative follow up will throw more light on the subject.

## References

1. Posnick JC, Wells M, Pron GE (1993) Pediatric facial fractures: evolving patterns of treatment. *J Oral Maxillofac Surg* 51: 836-844.
2. Zerfowski M, Bremerich A (1998) Facial trauma in children and adolescents. *Clin Oral Investig* 2: 120-124.
3. Wu Y, Long X, Fang W, Li B, Cheng Y, et al. (2012) Management of paediatric mandibular condylar fractures with screw-based semirigid intermaxillary fixation. *Int J Oral Maxillofac Surg* 41: 55- 60.
4. Pirttiniemi P, Peltomäki T, Müller L, Luder HU (2009) Abnormal mandibular growth and the condylar cartilage. *Eur J Orthod* 31: 1-11.
5. Myall RW, Sandor GK, Gregory CE (1987) Are you overlooking fractures of the mandibular condyle? *Pediatrics* 79: 639-641.
6. Choi J, Oh N, Kim IK (2005) A follow-up study of condyle fracture in children. *Int J Oral Maxillofac Surg* 34: 851-858.
7. Lindahl L, Hollender L (1977) Condylar fractures of the mandible: a radiographic study of remodelling processes in the temporomandibular joint. *Int J Oral Surg* 6: 153-165.
8. Xiang GL, Long X, Deng MH, Han QC, Meng QG, et al. (2014) A retrospective study of temporomandibular joint ankylosis secondary to surgical treatment of mandibular condylar fractures. *Br J Oral Maxillofac Surg* 52: 270-274.
9. Wang P, Yang J, Yu Q (2009) MR imaging assessment of temporomandibular joint soft tissue injuries in dislocated and nondislocated mandibular condylar fractures. *AJNR Am J Neuroradiol* 30: 59-63.
10. Dwivedi AN, Tripathi R, Gupta PK, Tripathi S, Garg S (2012) Magnetic resonance imaging evaluation of temporomandibular joint and associated soft tissue changes following acute condylar injury. *J Oral Maxillofac Surg* 70: 2829-2834.
11. Gerhard S, Ennemoser T, Rudisch A, Emshoff R (2007) Condylar injury: magnetic resonance imaging findings of temporomandibular joint soft-tissue changes. *Int J Oral Maxillofac Surg* 36: 214-218.
12. Villarreal PM, Monje F, Junquera LM, Mateo J, Morillo AJ, et al. (2004) Mandibular condyle fractures: determinants of treatment and outcome. *J Oral Maxillofac Surg* 62: 155-163.
13. Iatrou I, Theologie-Lygidakis N, Tzerbos F (2010) Surgical protocols and outcome for the treatment of maxillofacial fractures in children: 9 years' experience. *J Craniomaxillofac Surg* 38: 511-516.
14. Zide MF (1989) Open reduction of mandibular condyle fractures. Indications and technique. *Clin Plast Surg* 16: 69-76.
15. Eskitascioglu T, Ozyazgan I, Coruh A, Gunay GK, Yuksel E (2009) Retrospective analysis of two hundred thirty-five pediatric mandibular fracture cases. *Ann Plast Surg* 63: 522-530.
16. Neff A, Chossegross C, Blank JL, Champsaur P, Cheynet F, et al. (2014) Position paper from the IBRA Symposium on Surgery of the Head--the 2nd International Symposium for Condylar Fracture Osteosynthesis, Marseille, France 2012. *J Craniomaxillofac Surg* 42: 1234-1249.
17. Rampaso CL, Mattioli TM, de Andrade Sobrinho J, Rapoport A (2012) Evaluation of prevalence in the treatment of mandible condyle fractures. *Rev Col Bras Cir* 39: 373-376.
18. Zhao YM, Yang J, Bai RC, Ge LH, Zhang Y (2014) A retrospective study of using removable occlusal splint in the treatment of condylar fracture in children. *J Craniomaxillofac Surg* 42: 1078-1082.
19. Boffano P, Roccia F, Schellino E, Baietto F, Gallesio C, et al. (2012) Conservative treatment of unilateral displaced condylar fractures in children with mixed dentition. *J Craniofac Surg* 23: 376-378.
20. Boffano P, Roccia F, Schellino E, Baietto F, Gallesio C, et al. (2012) Conservative treatment of unilateral displaced condylar fractures in children with mixed dentition. *J Craniofac Surg* 23: e376-378.
21. Tabrizi R, Langner NJ, Zamiri B, Aliabadi E, Daneste H, et al. (2013) Comparison of nonsurgical treatment options in pediatric condylar fractures: rigid intermaxillary fixation versus using guiding elastic therapy. *J Craniofac Surg* 24: 203-206.
22. Zhou HH, Han J, Li ZB (2014) Conservative treatment of

- bilateral condylar fractures in children: case report and review of the literature. *Int J Pediatr Otorhinolaryngol* 78: 1557-1562.
23. Theologie-Lygidakis N, Chatzidimitriou K, Tzerbos F, Gouzioti A, Iatrou I (2016) Nonsurgical management of condylar fractures in children: A 15-year clinical retrospective study. *J Craniomaxillofac Surg* 44: 85-93.
  24. Lekven N, Neppelberg E, Tornes K (2011) Long-term follow-up of mandibular condylar fractures in children. *J Oral Maxillofac Surg* 69: 2853-2859.
  25. Thorén H, Hallikainen D, Iizuka T, Lindqvist C (2001) Condylar process fractures in children: a follow-up study of fractures with total dislocation of the condyle from the glenoid fossa. *J Oral Maxillofac Surg* 59: 768-773.
  26. Defabianis P (2003) Post-traumatic TMJ internal derangement: impact on facial growth (findings in a pediatric age group). *J Clin Pediatr Dent* 27: 297-303.
  27. Proffit WR, Vig KWL, Turvey TA (1980) Early fracture of mandibular condyles: Frequently an unsuspected cause of growth disturbances. *Am J Orthod* 78: 1-24.
  28. Gupta M, Iyer N, Das D, Nagaraj J (2012) Analysis of different treatment protocols for fractures of condylar process of mandible. *J Oral Maxillofac Surg* 70: 83-91.
  29. Ellis E, Throckmorton G (2000) Facial symmetry after closed and open treatment of fractures of the mandibular condylar process. *J Oral Maxillofac Surg* 58: 719-728.
  30. Kahl B, Fischbach R, Gerlach KL (1995) Temporomandibular joint morphology in children after treatment of condylar fractures with functional appliance therapy: a follow-up study using computed tomography. *Dentomaxillofac Radiol* 24: 37-45.
  31. Thorén H, Iizuka T, Hallikainen D, Lindqvist C (1998) Radiologic changes of the temporomandibular joint after condylar fractures in childhood. *Oral Surg Oral Med Oral Pathol Oral Radiol Endod* 86: 738-745.
  32. Kahl-Nieke B, Fischbach R (1998) Condylar restoration after early TMJ fractures and functional appliance therapy. Part I: Remodelling. *J Orofac Orthop* 59: 150-162.
  33. Strobl H, Emschhoff R, Röthler G (1999) Conservative treatment of unilateral condylar fractures in children: a long-term clinical and radiologic follow-up of 55 patients. *Int J Oral Maxillofac Surg* 28: 95-98.
  34. Sforza C, Tartaglia GM, Lovecchio N, Ugolini A, Monteverdi R, et al. (2009) Mandibular movements at maximum mouth opening and EMG activity of masticatory and neck muscles in patients rehabilitated after a mandibular condyle fracture. *J Craniomaxillofac Surg* 37: 327-333.
  35. Sforza C, Ugolini A, Sozzi D, Galante D, Mapelli A, et al. (2011) Threedimensional mandibular motion after closed and open reduction of unilateral mandibular condylar process fractures. *J Craniomaxillofac Surg* 39: 249-255.
  36. Hjorth T, Melsen B, Moller E (1997) Masticatory muscle function after unilateral condylar fractures: a prospective and quantitative electromyographic study. *Eur J Oral Sci* 105: 298-304.
  37. Kaban LB (1996) Facial Trauma II Dentoalveolar injuries and mandibular fractures in Pediatric Oral and Maxillofacial surgery, Troulis JM 441-461.
  38. Dodson TB (1995) Mandibular fractures in children, OMS Knowledge update 1 (part II) 95-107.
  39. Iida S, Matsuya T (2002) pediatric maxillofacial fractures: Their etiological characters and fracture patterns, *J Craniomaxillofac Surg* 30: 237-241.
  40. Posnick JC, Goldstein JA (1993) surgical management of temporomandibular joint ankylosis in the pediatric population. *Plast Reconstr Surg* 91:791-98.
  41. Kaban LB, Mulliken JB, Murray JE (1977) Facial fractures in children: An analysis of 122 fractures in 109 patients, *Plast Reconst Surg* 59: 15-20.
  42. Koeing WR, Olsson AB, Pensler JM (1994) the fate of developing teeth in facial trauma: Tooth buds in the line of mandibular fractures in children, *Ann Plas Surg* 32: 503-505.
  43. Lund K (1974) Mandibular growth and remodeling processes after condylar fracture: A longitudinal roentgencephalometric study, *Acta odontol Scand* 32: 113-117.
  44. Kaban LB (1990) Facial trauma II. Dentoalveolar injuries and mandibular trauma. In Kban LB (Ed). *Pediatric oral and Maxillofacial Surgery*, Philadelphia, WB Saunders 233-260.
  45. Leake DJ, Doyoks L, Habal MB (1971) Long-term follow-up of fractures of mandibular condyle in children, *Plast Reconstr Surg* 47: 127-131.
  46. Lustmann J, Milhem I (1994) Mandibular fractures in infants: Review of the literature and report of seven cases. *J Oral Maxillofac Surg* 52: 240-246.
  47. Thoren H, Iizuka T, Hallikainen D (1997) An epidemiological study of patterns of condylar fractures in children. *Br J Oral Maxillofac Surg* 35: 306-311.
  48. L Dahlstrom, K E Kahnberg, L Lindahl (1989) "15 Years Follow-Up on Condylar Fractures," *International Journal of Oral and Maxillofacial Surgery*. 18: 18-23.
  49. P. A. Banks (1998) "Pragmatic Approach to the Management of Condylar Fractures," *International Journal of Oral and Maxillofacial Surgery* 27: 244-246.
  50. R R Bos, R P Ward Booth, L G de Bont (1999) "Mandibular Condyle Fractures: A Consensus". *British Journal of Oral and Maxillofacial Surgery* 37: 87-89.
  51. O Fasola, E A Nyako, A E Obiechina (2003) "Trends in the Characteristics of Maxillofacial Fractures in Nigeria," *Journal of Oral and Maxillofacial Surgery* 61: 1140-1143.
  52. Alkan M. Metin, M. Muglali (2007) "Biomechanical Comparison of Plating Techniques for Fractures of the Mandibular Condyle," *British Journal of Oral and Maxillofacial Surgery* 45: 145-149.
  53. L. Asprino, S. Consani, M. De Moraes (2006) "A Comparative Biomechanical Evaluation of Mandibular Condyle Fracture Plating Techniques," *Journal of Oral and Maxillofacial Surgery* 64: 452-456.
  54. L A Assael (2003) "Open versus Closed Reduction of Adult Mandibular Condyle Fractures: An Alternative Interpretation of the Evidence," *Journal of Oral and Maxillofacial Surgery*. 61: 1333-1339.
  55. M Hawitschka, U Ecklet (2002) "Assessment of Patients Treated for Intra-Capsular Fractures of the Mandibular Condyle by Closed Techniques," *Journal of Oral and Maxillofacial Surgery* 60: 784-791.
  56. M L R Hlawitschka, U Eckelt (2005) "Functional and Radiological Results of Open and Closed Treatment If Intracapsular (Diacapitular) Condylar Fractures of the Mandible," *International Journal of Oral and Maxillofacial Surgery* 34: 597-604.
  57. W Baker, J McMahon, K F Moss (1998) "Current Consensus on the Management of Fractures of the Mandibular Condyle," *International Journal of Oral and Maxillofacial Surgery* 27: 258-266.
  58. J. Andersson, F. Hallmer, L Eriksson (2007) "Unilateral

- 
- Mandibular Condylar Fractures: 31-Year Follow-Up of Non-Surgical Treatment,” *International Journal of Oral and Maxillofacial Surgery* 36: 310-314.
59. Narayanan V, Kannan R, Sreekumar K (2009) Retromandibular approach for reduction and fixation of mandibular condylar fractures: a clinical experience. *Int J Oral Maxillofac Surg* 38: 835-839.
  60. Tang W, Gao C, Long J, Lin Y, Wang H, et al. (2009) Application of modified retromandibular approach indirectly from the anterior edge of the parotid gland in the surgical treatment of condylar fracture. *J Oral Maxillofac Surg* 67: 552-558.
  61. Biglioli F, Colletti G (2009) Transmasseter approach to condylar fractures by miniretromandibular access. *J Oral Maxillofac Surg* 67: 2418-2424.
  62. Devlin MF, Hislop WS, Carton AT (2002) Open reduction and internal fixation of fractured mandibular condyles by a retromandibular approach: surgical morbidity and informed consent. *Br J Oral Maxillofac Surg* 40: 23-25.
  63. Eckelt U, Schneider M, Erasmus F, Gerlach KL, Kuhlisch E, et al. (2006) Open versus closed treatment of fractures of the mandibular condylar process: a prospective randomized multi-centre study. *J Craniomaxillofac Surg* 34: 306-314.
  64. K Ragupathy (2016) Outcomes of surgical versus nonsurgical treatment of mandibular condyle fractures *International Surgery Journal* Ragupathy K. *Int Surg J* 3: 47-51.
  65. Ellis 3rd E, McFadden D, Simon P, Throckmorton G (2000) Surgical complications with open treatment of mandibular condylar process fractures. *J Oral Maxillofac Surg* 58: 950-958.
  66. Handschel J, Rugeberg T, Depprich R, Schwarz F, Meyer U, et al. (2012) Comparison of various approaches for the treatment of fractures of the mandibular condylar process. *J Craniomaxillofac Surg* 40: e397-e401.
  67. Haug, M. T. Brandt (2003) “Open versus Closed Reduction of Adult Mandibular Condyle Fractures: A Review of the Literature Regarding the Evolution of Current Thoughts on Management,” *Journal of Oral and Maxillofacial Surgery* 61: 1324-1332.
  68. Worsaae N, Thorn JJ (1994) Surgical versus nonsurgical treatment of unilateral dislocated low subcondylar fractures. *J Oral Maxillofac Surg* 52: 353-360.

**Citation:** *Majed Alharbi and Hamada Mahran (2018). Comparative Study between IMF and Pure Conservation in Management of Condylar Head Fracture in Children. Journal of Medical & Clinical Research 3(2):1-6.*

**Copyright:** ©2018 Hamada Mahran. This is an open-access article distributed under the terms of the Creative Commons Attribution License, which permits unrestricted use, distribution, and reproduction in any medium, provided the original author and source are credited.