

E. coli Causing De Novo Bile Duct Stone Association Revisited

Jeremy Lee Kay Hock^{1*} and Stephen Chang Kin Yong^{2,3}

¹College of Medicine and Health, University College of Cork, Ireland

²GLAD Clinic, Farrer Park Hospital, Singapore

³Department of Surgery, Yong Loo Lin School of Medicine, National University of Singapore, Singapore

***Corresponding author**

Jeremy Lee Kay Hock, Orchard Gardens, Cork, Ireland. Tel: +353 0831817939; E-mail: j-lee95@hotmail.com

Submitted: 11 Sep 2019; Accepted: 24 Sep 2019; Published: 01 Oct 2019

Abstract

The finding of a common bile duct (CBD) stone after living donor liver transplant (LDLT) is a rare occurrence. We report a case of a post-transplant patient who was admitted for gastroenteritis caused by *Escherichia coli* (*E.coli*). Three weeks later, following the acute episode, he developed a CBD stone. We hypothesize that ascending infection by *E.coli* in immunocompromised patients plays a role in the pathogenesis of CBD stone formation.

Keywords: Living Donor Liver Transplant, Common Bile Duct Stone, *E.coli*

Introduction

Biliary complications, the ‘Achilles heel’ of LDLT remains a common source of morbidity and mortality in patients [1,2]. Hepatic artery thrombosis, ischaemia-reperfusion injury and biliary infections are common causes of biliary complications and subsequent biliary stone formation [3].

Bile duct stones are known to be associated with bacterial infection, with *E.coli* as the predominant bacteria [4]. Maki et al. demonstrated that the enzymatic activity of *E.coli* plays a key role in pathogenesis of pigmented gallstones [5]. We present a case of a patient who is on immunosuppressant following LDLT, who had recent gastroenteritis with *E.coli*, developing primary bile duct stones [6].

Case Report

A 53-year-old Chinese man who is on immunosuppressant, following LDLT performed five months ago, presented to the hospital with a one day history of gastroenteritis caused by *E.coli*. At the time of his admission, he was hypotensive (65/52 mmHg), tachycardic (139 bpm) and pyrexia (37.5 degrees Celsius). Blood cultures revealed *E.coli* as the causative organism. He was treated with Azithromycin for his *E.coli*, and there was a subsequent resolution of his gastroenteritis.

Following the resolution of his gastroenteritis, his liver function test (LFT) showed normalization and improvement. Total bilirubin (73 to 15 umol/L), ALT (249 to 106 U/L), AST (210 to 50 U/L), GGT (900 to 221 U/L) and ALP (163 to 84 U/L) decreased towards near normal levels (Figure 1).

However one month later, there was an acute exacerbation of his LFTs, which showed a marked increase in ALT (106 to 527 U/L), AST (50 to 248 U/L), GGT (221 to 1049 U/L) and ALP (84 to 260 U/L). A magnetic resonance cholangiopancreatography (MRCP) was conducted, revealing biliary dilatation and CBD stone. An endoscopic retrograde cholangiopancreatography (ERCP) was later performed to remove the CBD stone.

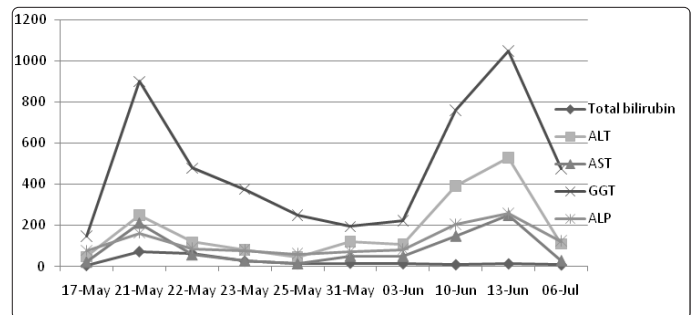


Figure 1: Series of LFTs taken for our patient

Discussion

Bacteria infections have been known to play a structural and functional role of the formation of pigment and cholesterol gallstones. Scanning electron microscopic (SEM) studies reaffirmed the findings of bacteria in pigment gallstones and the pigment portion of ‘‘composite’’ stones [7, 8]. Speer et al. also reported the presence of bacteria in cholesterol stones and suggested an association of the role of bacteria in both cholesterol and pigment stone formation [9].

In our case report, our patient had undergone LDLT and was commenced on long term immunosuppressant five months prior to his presentation to hospital with a bout of gastroenteritis caused

by E.coli, along with findings three weeks later of a CBD stone by MRCP.

Pathogenesis of E.coli and Gallstone Formation after LDLT

Following LDLT, immunosuppressive agents are used. A major side effect is bone marrow suppression leading to increased risk of fulminant infections. E.coli is the predominant pathogen for ascending infection in the bile duct [10].

As mentioned previously, infection contributes to the creation of brown pigment stones. Clemente et al. had isolated 133 microorganisms from the bile of 73 patients with intrahepatic stone and E.coli is the predominant microorganism.

Some of the possible infective ways include ascending infection via the sphincter of oddi (SOD), haematogenous dissemination via portal system and also spread via the lymphatic system. Ascending infection can cause damage to the bile duct mucosa. Consequently, this will promote bile duct stone recurrence.

There are several ways in which E.coli can promote the formation of bile duct stones [11-14]:

E.coli infecting the biliary duct via ascending infection is capable of converting conjugated bilirubin to unconjugated bilirubin. The bacteria contain an enzyme, β -glucuronidase, which hydrolyses bilirubin glucuronide into free bilirubin and glucuronic acid. Calcium levels will also rise in the biliary tract in inflammatory conditions. Calcium then binds to the free bilirubin at its free carboxyl radical to yield water-insoluble calcium bilirubinate.

E.coli produces phospholipase A1 which turns phosphatidylcholine to free fatty acids and lysophosphatidylcholine. This stimulates the deposition of fatty acid calcium and secretion of mucin from bile duct epithelium, enhancing stone formation.

Endotoxins produced by E.coli stimulate liver cells, bile duct epithelium cells and white blood cells in bile to release β -glucuronidase, increasing stone formation.

E.coli contains lipopolysaccharide which increases production of mucin 5AC (MUC5AC) through the tumour necrosis factor-converting enzyme (TACE)/transforming growth factor- α (TNF- α)/growth factor receptor (EGFR) pathway in biliary epithelial cells. This results in increased mucosity and bile flow reduction. Meanwhile, bacterial infection exacerbates cholestasis and cholangitic stenosis, thus promoting the formation of stones.

Summary

In summary patients with E.coli septicaemia may be more prone to bile duct stone formation especially in immunocompromised patients. A high index of suspicion should prompt early radiological investigations of the biliary system.

References

1. Ayman ZakiAzzam (2017) Biliary complications after living donor liver transplantation: A retrospective analysis of the Kyoto experience 1999-2004. Indian Journal of Gastroenterology 7: 296-304.
2. Wang SF (2011) Biliary complications after living donor liver transplantation. Liver Transpl 17: 1127-1136.
3. Maciej Wojcicki (2008) Biliary Tract Complications after Liver Transplantation: A Review. Dig Surg 25: 245-257.
4. G. Clemente, A M De Rose, R Murri, F Ardito, G Nuzzo, et al. (2016) Liver resection for primary intrahepatic stones: focus on postoperative infectious complications. World Journal of Surgery 40: 433-439.
5. Maki T (192) A Study on The Activity of Beta-Glucuronidase in Bile in Connection with precipitation of Calcium Bilirubinate. Tohoku J Exp Med 77: 179-186.
6. H S Kaufman (1989) The Role of Bacteria in Gallbladder and Common Duct Stone Formation. Ann Surg 209: 584-592.
7. Stewart L, Smith AL, Pellegrini CA, Motson RW, Way LW, et al. (1987) Pigment gallstones form as a composite of bacterial microcolonies and pigment solids. Ann Surg 206: 242-250.
8. Smith A, Stewart L, Pellegrini C, Way L (1988) Gallstone disease: the clinical manifestations of infectious stones. Arch Surg 124: 629-633.
9. Speer AG, Cotton PB, Costerton JW, Rode J, Seddon AM, et al. (1988) Bacteria adhere to cholesterol gallstones. Gastroenterology 94:A593.
10. Cetta F (1991) The role of bacteria in pigment gallstone disease. Ann Surg 213: 315-326.
11. Hashimoto T (1956) Studies on Hydrogen Ion Concentration and Calcium Content of Bile. II. Results with Pathological Bile. Hirosaki Med. J. (Jap.) 7: 331.
12. Z Liu, F Tian, X Feng, He Y, Jiang P, et al. (2013) LPS increases MUC5AC by TACE/TGF- α /EGFR pathway in human intrahepatic biliary epithelial cell. BioMed Research International 2013: 1-8.
13. Li FY1, Cheng NS, Mao H, Jiang LS, Cheng JQ, et al. (2009) Significance of controlling chronic proliferative cholangitis in the treatment of hepatolithiasis. World Journal of Surgery 33: 2155-2160.
14. Xi Ran, Baobing Yin, Baojin Ma (2017) Four major factors contributing to intrahepatic stones. Gastroenterology Research and Practice 2017: 1-5.

Citation: Jeremy Lee Kay Hock, Stephen Chang Kin Yong (2019) E. coli Causing De Novo Bile Duct Stone Association Revisited. Med Clin Res 4(10): 1-2.

Copyright: ©2019 Jeremy Lee Kay Hock, et al. This is an open-access article distributed under the terms of the Creative Commons Attribution License, which permits unrestricted use, distribution, and reproduction in any medium, provided the original author and source are credited.