

Myasthenia Cardiomyopathy Silent Myocarditis Unveiled by Cardiovascular Magnetic Resonance

Yasmin Hanfi¹, Dominique Auger¹, Dudley J Pennell*¹ and FMedSci^{1,2}

¹Cardiovascular Magnetic Resonance Unit, Royal Brompton Hospital, London, UK

²Imperial College London, UK

*Corresponding author

Prof. Dudley Pennell, MD, CMR Unit, Royal Brompton Hospital, Sydney Street, London SW3 6NP. E-mail: D.pennell@ic.ac.uk.

Submitted: 20 Feb 2018; Accepted: 27 Feb 2018; Published: 15 Mar 2019

Introduction

In myastheniagravis (MG) patients, heart muscle is one of the autoimmune targets. The presentation of cardiac involvement with MG varies and may include myocarditis. Beyond comprehensive left ventricular volume and ejection fraction quantification, cardiovascular magnetic resonance (CMR) provides incomparable non-invasive tissue characterisation. Hence, CMR in MG may allow early detection of subclinical myocarditis or evaluation of remote myocardial damage by late gadolinium enhancement technique. We present the first case of cardiac involvement of immune-mediated myocarditis imaged by CMR in MG.

Case report

A 74 year old male with a long time diagnosis of myasthenia gravis (MG) and previous thymectomy presented at Royal Brompton Hospital CMR Unit for cardiac assessment. This very active patient had been referred with recent new onset shortness of breath. His current therapy consisted of a cholinesterase inhibitor (Mestinon) and corticosteroid therapy (prednisolone). In the context of exercise related dyspnea, ischaemic assessment with adenosine perfusion CMR and late gadolinium enhancement was planned to rule out coronary artery disease.

CMR confirmed the septal hypertrophy reaching 14mm with a non-stenotic and competent aortic valve. The rest cine images of the left ventricle showed overall normal left ventricular (LV) ejection fraction, but hypokinesia of the basal segments involving the septum, inferior and lateral walls. The mid and apical left ventricular segments were contracting normally. There was no inducible myocardial ischemia. On late gadolinium enhancement study, there were areas of high signal intensity within the mid myocardial layer of the hypokinetic basal, inferior and inferolateral segments (Figure 1). In addition, there was mid-wall enhancement of the normally contracting mid inferolateral wall. No pericardial effusion or other valvulopathy was found.

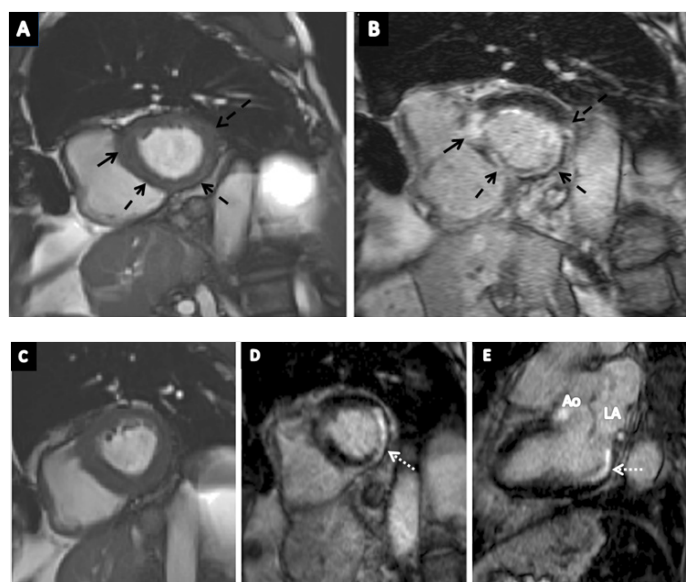


Figure 1: A) MG patient with localised interventricular septal (IVS) hypertrophy (black arrow) and hypokinesia of the basal septal, inferior and lateral walls (dashed black arrows). B) Late gadolinium enhancement image of the same slice with enhancement of the IVS as well as circumferential enhancement of the septum, inferior and lateral walls (dashed arrows). C) Mid left ventricular short axis slice at end diastole. D) Late gadolinium enhancement of the inferolateral wall (dotted white arrow). E) Vertical long axis view with late gadolinium enhancement of the inferolateral wall (dotted white arrow). Ao (aorta), LA (left atrium).

Discussion

Myasthenia Gravis is an autoimmune neuromuscular disorder characterised by skeletal muscle involvement causing muscle weakness and fatigue that needs immunomodulatory treatment [1]. MG may be associated with thymoma [2]. MG patients who carry antibodies against titin or ryanodine receptors are strongly associated with thymoma and may have a severe phenotype [3].

There are few reports describing cardiac involvement in MG, which describe overt cardiomyopathy and life threatening myocarditis, diagnosed using endomyocardial biopsy (EMB). EMB is the gold standard to define the active inflammatory destruction of myocytes in myocarditis, whether by cardiac infection or auto-immunity.

EMB is invasive and its accuracy requires multiple specimens and it is therefore usually reserved for serious cases [4]. Cardiovascular magnetic resonance (CMR) is the only non-invasive diagnostic imaging technique that can detect myocarditis, but has not before been described in MG [5].

The results of the CMR in our case, show it can identify silent myocarditis in MG. This may lead to an early start of cardiac medication according to ACC/AHA guidelines, and thus potentially modulating the progression of myocarditis to dilated cardiomyopathy and heart transplantation [6].

References

1. Mavrogeni S, Ntoskas T, Gialafos E, Karabela G, Krommida M et al. (2016) Silent myocarditis in myasthenia gravis. Role of cardiovascular magnetic resonance imaging. *Int J Cardiol* 202: 629-630.
2. Goldstein G (1971) Myasthenia gravis and the thymus. *Annu Rev Med* 22: 119-124.
3. Bernard C, Frih H, Pasquet F, Kerever S, Jamilloux Y, et al. (2016) Thymoma associated with autoimmune diseases: 85 cases and literature review. *Autoimmun Rev* 15: 82-92.
4. Caforio AL, Pankuweit S, Arbustini E, Basso C, Gimeno-Blanes J, et al. (2013) European Society of Cardiology Working Group on Myocardial and Pericardial Diseases. Current state of knowledge on aetiology, diagnosis, management, and therapy of myocarditis: a position statement of the European Society of Cardiology Working Group on Myocardial and Pericardial Diseases. *Eur Heart J* 34: 2636-2648.
5. Friedrich MG, Sechtem U, Schulz-Menger J, Holmvang G, Alakija P, et al. (2009) International Consensus Group on Cardiovascular Magnetic Resonance in Myocarditis. Cardiovascular magnetic resonance in myocarditis: A JACC White Paper. *J Am Coll Cardiol* 53: 1475-1487.
6. Hunt SA, Abraham WT, Chin MH, Feldman AM, Francis GS, et al. (2005) American College of Cardiology.; American Heart Association Task Force on Practice Guidelines; American College of Chest Physicians.; International Society for Heart and Lung Transplantation.; Heart Rhythm Society. ACC/AHA 2005 Guideline Update for the Diagnosis and Management of Chronic Heart Failure in the Adult: a report of the American College of Cardiology/American Heart Association Task Force on Practice Guidelines (Writing Committee to Update the 2001 Guidelines for the Evaluation and Management of Heart Failure): developed in collaboration with the American College of Chest Physicians and the International Society for Heart and Lung Transplantation: endorsed by the Heart Rhythm Society. *Circulation* 112: e154-235.

Citation: Yasmin Hanfi, Dominique Auger, Dudley J Pennell and FMedSci (2019). Myasthenia Cardiomyopathy Silent Myocarditis Unveiled by Cardiovascular Magnetic Resonance. *Journal of Medical & Clinical Research* 4(3):1-2.

Copyright: ©2019 Prof. Dudley J Pennell, et al. This is an open-access article distributed under the terms of the Creative Commons Attribution License, which permits unrestricted use, distribution, and reproduction in any medium, provided the original author and source are credited.