

## PFN (Proximal Femoral Nail): review of recent study

Saccomanni Bernardino\*

Department of Orthopaedic and Trauma Surgery, viale Regina Margherita, 70022, Altamura (Bari), Italy.

### \*Corresponding author

Saccomanni Bernardino, Department of Orthopaedic and Trauma Surgery, viale Regina Margherita, 70022, Altamura (Bari), Italy.

Submitted: 25 Apr 2022; Accepted: 30 Apr 2022; Published: 07 May 2022

**Citation:** Saccomanni Bernardino (2022) PFN (Proximal Femoral Nail): review of recent study. *Medical & Clinical Research* 7(5):01-05.

### Abstract

The PFN-A™ device is a proximal reconstruction nail whose implantation is simple and fast. The helical blade may confer additional benefits in patients with osteoporotic trochanteric fractures, both by preventing rotation and by ensuring cancellous bone compaction. This design may diminish the rate of complications associated with the cervical implant, provided the implantation procedure is scrupulously followed and fracture reduction is optimal. Our results should be interpreted with caution until the results of an on-going prospective study become available.

**Keywords:** Pertrochanteric hip fracture, PFN-A™.

### Introduction

Proximal femoral fractures (PFFs) account for a substantial proportion of trauma surgery procedures and carry high mortality rates of 5% after 1 month and 15% after 6 months [1]. The incidence of PFFs has risen steadily in recent years, increasing in France and in Italy from 50,000 cases in 1990 to 75,000 cases in 2002 [2], with a projected value of 145,000 in 2050 [3]. Among PFFs, 65% are extra-capsular [4]. The main challenge with extra-capsular PFFs is instability in the event of comminution and rupture of the posteromedial cortex, as seen in complex pertrochanteric fractures, intertrochanteric fractures, trochanteric fractures extending into the diaphysis, and subtrochanteric fractures [5]. Instability permits varus deviation and lateral rotation of the femoral head [6].

The introduction of dynamic screw-plates and proximal intramedullary reconstruction nails has transformed the management of extra-capsular PFFs. Whether one of these devices is superior over the other remains controversial, particularly as their introduction coincided with a decline in complication rates due to increasing surgeon experience [7]. The rate of reoperation for mechanical complications of any type remains as high as 8% [8]. Mechanical complications include hardware-related fractures and blade cut-out with a risk of acetabular penetration [4,9]. Greater fracture instability and osteoporosis severity are associated with a higher risk of mechanical complications [4,9].

The proximal femoral nail antirotation1 (PFN-A™, AO-ASIF) was designed to minimise the risk of mechanical complications, and preliminary results suggest that this goal may have been achieved [10, 11]. We hypothesized that the helical blade of the PFN-A™ resulted in better cancellous bone compaction in the femoral neck,

thereby decreasing the risk of secondary displacement. To test this hypothesis, we conducted a retrospective evaluation of hardware-related mechanical complication rates and of fracture union rates.

### Materials and Methods

#### Patients

We conducted a single-centre multi-surgeon retrospective study of the 108 patients older than 70 years who underwent PFN-A™ implantation for non-pathological traumatic extra-capsular PFFs between January 2007 and December 2008. None of the patients was lost to follow-up. Six patients died during the immediate postoperative period and were excluded from the analysis. At last follow-up, 37 of the remaining patients had died; the clinical and imaging data obtained at the last visit in these 37 patients were used for the study. Thus, 102 fractures managed with PFN-A™ in 102 patients were included.

During the study period, PFN-A™ was used in all patients older than 70 years of age who had trauma-related extra-capsular PFFs. Patients younger than 70 years of age and patients with intra-capsular femoral neck fractures were not eligible for the study.

The 102 study patients had a mean age of  $84.9 \pm 9.5$  years (70-100 years) and a female-to-male ratio of 2.8 (75 females and 27 males). The mean body mass index (BMI) was  $24.1 \text{ kg/m}^2$  (17-33) and 14 (14%) patients had BMI values greater than  $30 \text{ kg/m}^2$ . In the American Society of Anesthesiologists classification system, 99 (97%) patients were class 2 or 3. The fractures were classified according to the AO system for PFFs [12] based on the initial radiographs (Table 1). Type A1 fractures were considered stable and type A2 and A3 fractures unstable.

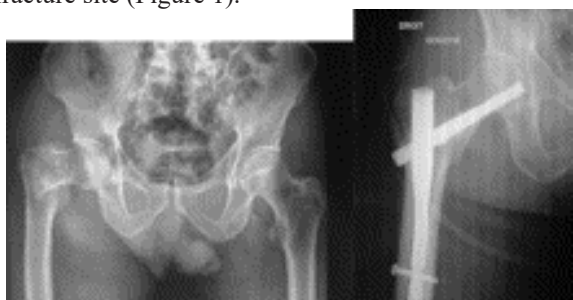**Table 1: Main features in the study patients.**

	Number of patients	Number of patients dead at last follow-up
ASA class		
1	5	0
2	58	17
3	39	20
AO classification		
A1	45	16
A2	41	18
A3	16	3
BMI, kg/m <sup>2</sup>		
<25	60	27
>25	28	7
>30	14	3

ASA: American Society of Anesthesiologists;  
AO: Arbeitsgemeinschaft für Osteosynthesefragen (Society for Internal Fixation); BMI: body mass index.

### Material

The PFN-A™ device is a titanium reconstruction nail. Although this device is available in various lengths, diameters, and blade angles, all the study patients had implantation of the 200-mm nail measuring 10mm in diameter and having a blade-nail angle of 125°. The proximal nail angle in the coronal plane is 6°, to match human anatomy. An aiming device is used to achieve distal locking by inserting a screw through a hole that is either round (static locking) or olive-shaped (dynamic locking). The cephalic end of the device is a helical blade whose shape precludes rotation once locking is achieved but allows back-out to obtain compression of the fracture site (Figure 1).



**Figure 1:** PFN-A™ device with static locking ensuring compression of the A1 fracture via back-out of the helical blade: 3-month follow-up.

### Surgical Procedure and Postoperative Management

All patients had surgery within 48 hours of admission. After

anaesthesia induction, a single parenteral injection of 1.5 g of cefuroxime was given for prophylaxis. The patient was positioned on an orthopaedic surgical table. Reduction was performed in the coronal and sagittal planes under image-intensifier guidance. The blade was inserted by impaction through a hole drilled in the lateral femoral cortex. The aiming device was then used to insert the locking screw. Static locking of the neck-blade into the nail was chosen to allow fracture site compression only by the helical blade.

Low-molecular-weight heparin was given routinely to prevent thromboembolism. Rehabilitation was started on the second postoperative day by mobilization and full weight-bearing in all patients.

### Evaluation Criteria

Activity and function before the injury were assessed using the Parker Mobility Score (PMS) [13] (Table 2).

The patients were divided into two groups based on the clinical outcome 6 months after surgery: 74 (73%) patients had good or very good clinical outcomes (favourable-outcome group) and 28 (27%) had fair or poor clinical outcomes (unfavourable-outcome group). Classification into these two groups was based on functional capacity, with good and very good clinical outcomes being defined as a PMS decline no greater than 2 points compared to the pre-injury value, with no reoperation. For classification, we used the best PMS value recorded during follow-up and not the value at last follow-up, because delayed age-related functional impairments developed in 22 (21.5%) patients older than 85 years of age.

We recorded medical and surgical complications. Visits were scheduled 6 weeks, 3 months, 6 months, and 12 months after surgery. In addition, a last follow-up visit occurred between April and July 2011. Walking and pain were evaluated at each visit, and the PMS at last follow-up was recorded.

Blade position was recorded as in the upper half or lower half on the anteroposterior view and as in the anterior, middle, or posterior third on the lateral view. The ideal blade position according to the manufacturer is in the lower half on the anteroposterior view and in the middle third of the neck on the lateral view. Blade position was assessed by fluoroscopy during surgery. Anteroposterior and lateral radiographs were obtained immediately after surgery and at each follow-up visit to monitor bone healing, to assess blade position, and to look for blade back-out. We looked for mechanical complications such as blade cut-out, penetration of the blade into the joint cavity, hardware-related femoral fracture, and non-union.

**Table 2: Parker Mobility Score: the score is obtained by summing the points assigned to each item.**

	Yes, with no difficulty and no help	Yes, with an aid (walking stick or walker)	Yes, with help from another person	No
Indoor walking	3	2	1	0
Outdoor walking	3	2	1	0
Shopping	3	2	1	0

### Statistical Analysis

We compared patients with mechanical complications to those who experienced fracture union without complications. Among potential factors involved in treatment failure, we assessed general physical findings, the preoperative PMS, the type of fracture, and blade position in the neck. We also compared results in the favourable- and unfavourable-outcome groups described above. We evaluated whether age, BMI, ASA class, anticoagulant therapy, and/or antiplatelet therapy were significantly associated with complications and/or with reoperation. Between-group comparisons were with the Chi-square test or Fisher exact test, as appropriate, for qualitative variables, and the non-parametric Mann-Whitney test for quantitative variables. Values of  $P < 0.05$  were considered significant.

### Results

#### Clinical Findings

Mean operating time was 47min (11-127min). The operating time was greater than 60min in 20 (19.6%) patients including 10 with BMI values greater than 30 kg/m<sup>2</sup> (71% of patients in this BMI category) and 13 with unstable fractures (A2 or A3); the two

patients with none of these factors were treated by surgeons with limited experience who were not thoroughly familiar with the device.

At last follow-up, 65 (60%) of the 108 operated patients (50 females and 15 males) were alive. Six patients died during the immediate postoperative period. In addition, 37 patients died later on; time to death was less than 3 months in five patients, 3 to 6 months in 18 patients, 6 to 12 months in eight patients, 1 to 2 years in three patients, and 3 years in three patients. PMS values indicated a favourable outcome (good or very good result) in 74 (73%) patients and an unfavourable outcome (fair or poor result) in 28 (27%) patients. Significant loss of self-sufficiency occurred, with a 1.5-point decrease in the PMS after 3 months ( $P < 0.001$ ). At this time point, 49% of patients required assistive devices. After 6 months, there was a significant 1.1-point decrease in the PMS ( $P < 0.001$ ) and, although 85 (83%) patients had returned to their previous living arrangements, 34% of them required additional help at home. At last follow-up, only 63 (62%) of patients had no change in their living arrangements and the PMS had declined further, by 0.8 point ( $P < 0.001$ ) (Table 3).

**Table 3: Mean loss of function after internal fixation for trochanteric fractures.**

Parker Mobility Score	Baseline <i>n=102</i>	3 months <i>n=97</i>	6 months <i>n=79</i>	2 years (last follow-up) <i>n=65</i>
Mean (range)	5.3 (0-9)	3.8 (0-9)	4.2 (0-9)	3.4 (0-9)
0-3, n	27	47	33	35
4-6, n	35	33	26	11
7-9, n	40	17	20	19
Parker=9, n (%)	22 (22%)	5 (5%)	10 (13%)	9 (14%)
Parker=0, n (%)	9 (9%)	14 (14%)	10 (13%)	13 (20%)

#### Radiographic Findings

Mean time to healing was  $10.3 \pm 3$  weeks. None of the patients experienced non-union. Blade position was inappropriate in 18 (17.6%) patients (three with the blade in the upper half including one in the anterior third and 15 with the blade in the anterior or posterior third). During follow-up, posterior blade displacement permitted by the device to achieve fracture compaction was recorded in 16 patients (Figure 1). Femoral head displacement was noted in one patient.

#### Complications

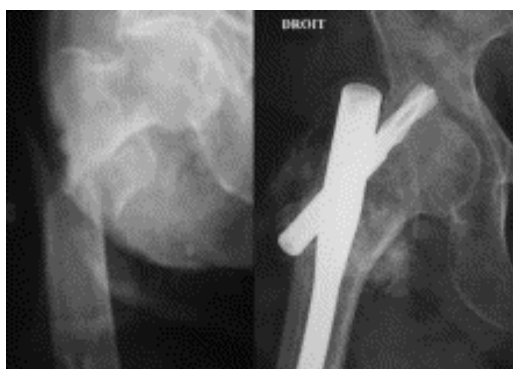
One or more medical complications occurred in 18 patients (Table 4). The morbidity rate was 16.7%. There were 12 postoperative surgical complications (morbidity rate, 11.1%) (Table 5), including two surgical-site infections, three instances of blade cut-out including one with acetabular penetration (Figure 2), two nail-related fractures, and five blade back-outs responsible for pain (Figure 3). The three patients with blade cut-out had unstable fractures (A2 in 2 and A3 in 1); among them, two had blade malposition, including the patient with acetabular penetration, and one had inadequate fracture reduction.

**Table 4: Postoperative medical complications.**

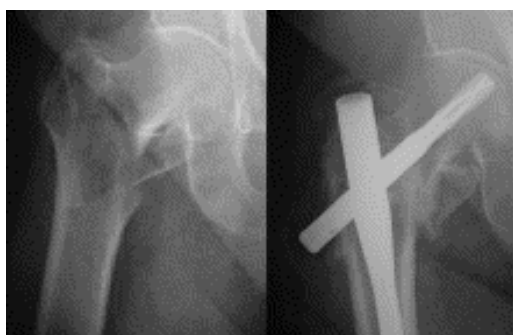Medical complications	Number of cases	Number of fatal cases
Lower respiratory tract infection	4	4
Pulmonary embolism	1	1
Heart failure decompensation	5	4
Gastrointestinal complications	4	2
Acute urinary retention	1	0
Urinary tract infection	2	1
Pressure sores	1	1

**Table 5: Postoperative surgical complications.**

Postoperative surgical complications	Number of patients	Reoperations	Deaths
Surgical-site infection	2	2	1
Cut-out without acetabular penetration	2	1	0
Cut-out with acetabular penetration	1	1	0
Hardware-related fracture	2	2	0
Fascia-lata pain related to marked back-out of the device	5	2	0



**Figure 2:** Acetabular penetration 13 months after PFN-A™ for an A2 pertrochanteric fracture.



**Figure 3:** Pain due to blade back-out 6 months after PFN-A™ for an A2 pertrochanteric fracture.

unstable fractures (A2 or A3) requiring operating times longer than 75min. One was an 84-year-old ASA-2 woman with a BMI of 32 kg/m<sup>2</sup> and chronic anticoagulant therapy; her operating time was 92min. The other was a 99-year-old ASA-3 woman with a BMI of 22 kg/m<sup>2</sup> and an operating time of 77min. In the 84-year-old patient, no microorganism was recovered despite protracted culturing; after multidisciplinary discussion, no antibiotics were given, and no recurrent infection had occurred at the surgical site at last follow-up. The 99-year-old patient had specimens positive for an oxacillin-resistant *Staphylococcus aureus* and was treated with rifampin and fusidic acid. This patient died after her transfer to a nursing home, with no specific cause of death being identified;

- Two patients required reoperation because of blade back-out due to fracture impaction and responsible for incapacitating pain in the fascia lata during walking. There was no varus deviation of the femoral head. In each patient, the blade was removed after fracture union was achieved. After this procedure, one of the patients experienced no further pain. The other patient continued to experience pain and underwent partial hip arthroplasty at another institution. After more than 4 years (51 months), her pain persisted and her PMS was 4 compared to 9 before the fracture and 7 before the intermediate hip arthroplasty;
- A patient with an A2 fracture had acetabular penetration of the blade and underwent removal of the device. This 80-year-old ASA-2 woman had a BMI of 21 kg/m<sup>2</sup> and a pre-injury PMS of 4. She was lost to follow-up for nearly 1 year then underwent blade removal 14 months after surgery, at a time when the fracture was healed and she was experiencing no major discomfort. Her PMS was 3 at last follow-up 21 months after the reoperation;

**Reoperation was required in eight (7.8%) patients:**

- The two patients with early surgical-site infection required reoperation for surgical-site lavage with intraoperative collection of multiple bacteriological specimens. Both had

- Blade back-out with leg length inequality due to femoral head displacement led to removal of the nail and total hip arthroplasty at another institution in a 79-year-old ASA-2 woman with a BMI of 24 kg/m<sup>2</sup>. More than 2 years (50 months) later, she had no pain and her PMS was 7 compared to 9 before the injury;
- Finally, two patients required reoperation for femoral diaphyseal fractures under the nail. In both cases, the reoperation consisted in implanting a long PFN-A™ nail. One of these patients was an 87-year-old man with a BMI of 25 kg/m<sup>2</sup> in whom the nail-related fracture occurred 2 years and 9 months after the initial injury. He died of slipping syndrome 3 months after the second surgical procedure. The other patient was a 65-year-old man with severe alcohol abuse, a BMI of 22.7 kg/m<sup>2</sup>, and precarious living conditions. The second fracture occurred after a fall 2 months after the first surgical procedure. At last follow-up after 4 months, his PMS was 9.

### Mortality and Criteria For Treatment Success

After 6 months, 29 (28%) of the 102 patients had died, and this number increased to 37 (36%) after 1 year. We identified no factors significantly associated with postoperative medical or surgical complications. Blade malposition was not significantly associated with the development of mechanical complications ( $P=0.256$ ). Statistical power was not sufficient to determine whether inadequate fracture reduction influenced the risk of mechanical complications.

The medical complication rate was higher in the older patients, i.e., 40.6% in the patients older than 85 years of age compared to 15.2% in younger patients ( $P=0.022$ ). The risk of medical complications was not significantly influenced by BMI, ASA class, or PMS value. However, ASA class was significantly associated with survival at last follow-up ( $P=0.033$ ).

The patients with the highest PMS values before the injury (indicating greater self-sufficiency) had higher rates of radiological complications including cut-out, acetabular penetration, and pain due to blade back-out ( $P=0.005$ ). Such complications occurred in 36.4% of patients with baseline PMS values between 7 and 9 compared to 20% of the other patients ( $P=0.031$ ). We ascribe this difference to faster resumption of physical activities and full weight-bearing in the patients with better mobility. In addition, higher BMI values were associated with a higher radiological complication rate (20.8% in patients whose BMI was greater than 25kg/m<sup>2</sup> compared to 2.7% in the other patients,  $P=0.031$ ). The occurrence of radiological complications was not significantly influenced by age, ASA class, function, or blade position on the anteroposterior or lateral view.

### Discussion

Controversy continues to surround the choice of fixation material for trochanteric fractures [8,14], although a consensus is beginning to take shape in the literature. Primary arthroplasty is rarely appropriate, except in patients with osteoarthritis, which increases

the risk of dislocation [15]. Choosing between a screw-plate and an intramedullary nail is more difficult [16]. In some studies, neither of these two options was superior over the other in terms of functional recovery or complication rates [17-19], whether others suggested higher complication rates with the gamma nail [20]. Bhandari et al. [7] found evidence that the increased risk of complications had been resolved by design improvements in third-generation gamma nails. In cadaveric studies, bending was more marked with the dynamic hip screw than with the gamma nail, which had a lower risk of cut-out [21,22]. The best indication for dynamic screw-plates may be stable pertrochanteric fractures (AO 31-A1 fractures, i.e., basicervical fractures and simple pertrochanteric fractures [5]). In patients with unstable fractures (AO 31-A.2 and 31-A.3 [23-25]), a reconstruction nail is more appropriate, particularly as this method is associated with better functional recovery [26]. Among reconstruction nails, the most widely used at present is the gamma nail, for which better tolerance has been reported in elderly patients compared to screw-plate fixation [27]. The gamma nail allows early mobilization and weight-bearing during the first few postoperative days [25] regardless of fracture type, with a very small failure rate compared to other internal fixation devices, some of which have failure rates of up to 17% [25,28-30]. The main complications reported in the literature are hardware-related fractures (2% to 3%), screw cut-out in the femoral head due to varus deviation (3% to 10%), and penetration of the screw into the joint (3% to 15%) [9,22,26,31,32,33]. The incidence of hardware-related fractures has been decreased by the design improvements introduced in third-generation gamma nails [7]. Cephalic screw cut-out is defined as an at least 5-mm displacement of the screw [34]. This multifactorial complication is related to the loads applied to the bone, type of fracture, quality of fracture reduction, and implant design [6,27].

The PFN-A™ device is a proximal reconstruction nail that is anchored in the femoral head by a helical blade. Few studies have assessed this method of cephalic fixation, which theoretically ensures rotational and angular stability with a single component [35,36], as well as cancellous bone compaction around the blade inserted by impaction [36]. Cancellous bone compaction improves anchoring in osteoporotic bone, thereby decreasing the risk of cut-out [11] as demonstrated in studies of cadaveric osteoporotic femoral heads comparatively with dynamic hip screw and gamma nail fixation [6]. A multicentre study by Simmermacher et al. [10] suggests that, by controlling the metaphyseal impaction, the helical blade may prevent penetration through the femoral head and allow full weight-bearing in over three-quarters of patients with unstable fractures.

Our results are comparable to those reported with the gamma nail in terms of operating time (30 to 90min on average [10,15,25,34]), functional score declines after 3 and 6 months [34], and mortality in the immediate postoperative period and after 6 months [2,24,34]. Blade back-out was rarely associated with complications, because the cause was femoral head impaction, allowed by the device. We recorded three surgical complications. All three were associated

with faulty technique during implantation of the device: blade malposition in the neck in all three patients and inadequate fracture reduction in one patient. However, we found no proof that blade malposition was the only factor responsible for cut-out. On the other hand, all cases of cut-out occurred in patients with incomplete reduction or unstable fractures, in keeping with previous data. Thus, the risk of cut-out is directly dependent on the quality of fracture reduction and on implant position [6,37].

Our study has a number of limitations. The design was retrospective. The PFN-A™ device was not compared to other internal fixation systems. However, our study is among the first to evaluate this new fixation device. The 2-year data with no patients lost to follow-up show a low complication rate. A comparison of our data to previous reports suggests that the PFN-A™ device may be preferable over dynamic hip screw fixation in patients with unstable fractures [38-40] but does not establish superiority over the gamma nail [41-43].

### Conclusions

The best surgical strategy for extra-capsular proximal femoral fractures (PFFs) is controversial in the elderly. Poor bone quality and neck screw instability can adversely affect the results with currently available fixation devices, which predominantly consist in dynamic hip screw-plates and proximal reconstruction nails.

The helical blade of the proximal femoral nail antirotation (PFN-A™) achieves better cancellous bone compaction in the femoral neck, thereby decreasing the risk of secondary displacement.

We retrospectively reviewed consecutive cases of PFN-A™ fixation performed between 2006 and 2008 in 102 patients (75 females and 27 males) with a mean age of  $84.9 \pm 9.5$  years (range, 70-100 years). Functional outcomes were assessed using the Parker Mobility Score.

Mean follow-up in the 102 patients was  $21.3 \pm 17.5$  months (4-51 months). Fracture distribution in the AO classification scheme was A1, n=45; A2, n=41; and A3, n=16. At last follow-up, Parker Mobility Score values in the 65 survivors were 0-3, n=35; 4-6, n=11; and 7-9, n=19. Fracture union was consistently achieved, after a mean of  $10.3 \pm 3$  weeks. Blade back-out allowed by the device design occurred in 16 (15.7%) patients but caused pain due to screw impingement on the fascia lata in only five patients (of whom two underwent reoperation). Cephalic blade cut-out was noted in three (2.9%) patients, of whom one required reoperation because of acetabular penetration. Two hardware-related fractures were recorded.

The new PFN-A™ device ensures reliable fixation with low mechanical complication rates. Although our data do not constitute proof that a helical blade is superior over a neck screw, they suggest a decreased rate of construct failure and may serve as a basis for a comparative study.

### References

1. Farahmand BY, Michaelsson K, Ahlbom A, Ljunghall S, Baron JA (2005) Survival after hip fracture Osteoporos Int 16 :1583-1590.
2. Rosencher N, Vielpeau C, Emmerich J, Fagnani F, Samama CM (2005) Venous thromboembolism and mortality after hip fracture surgery: the ESCORTE study J Thromb Haemost 3:2006-2014.
3. Baudoin C (1995) Present and future epidemiology of osteoporosis Rev Prat 45:1089-1095.
4. Bejui-Hugues J (1994) Ostéosynthèse des fractures trochantériennes Cahiers d'enseignement de la Sofcot Editors Paris: Expansion Scientifique Française 1-17.
5. Maury P, Putzeys P (1999) Complications des fractures trochantériennes et sous-trochantériennes Cahiers d'enseignement de la Sofcot France (1975): Elsevier Masson, Issy-les-Moulineaux 168-182.
6. Sommers MB, Roth C, Hall H, Kam BC, Ehmke LW, et al. (2004) A laboratory model to evaluate cutout resistance of implants for pertrochanteric fracture fixation J Orthop Trauma 18:361-368.
7. Bhandari M, Schemitsch E, Jonsson A, Zlowodzki M, Haidukewych GJ (2009) Gamma nails revisited: gamma nails versus compression hip screws in the management of intertrochanteric fractures of the hip: a meta-analysis J Orthop Trauma 23:460-464.
8. Nordin JY, Siguier M, Bonneville P, Chiron P, Laude F, et al. (2008) Hip controversies Rev Chir Orthop Reparatrice Appar Mot (94Suppl):S200-S210.
9. Fogagnolo F, Kfuri M, Paccola CA (2004) Intramedullary fixation of pertrochanteric hip fractures with the short AO-ASIF proximal femoral nail Arch Orthop Trauma Surg 124:31-37.
10. Simmermacher RK, Ljungqvist J, Bail H, Hockertz T, Vochteloo AJ, et al. (2008) The new proximal femoral nail antirotation (PFNA) in daily practice: results of a multicentre clinical study Injury 39:932-939.
11. Takigami I, Matsumoto K, Ohara A, Yamanaka K, Naganawa T, et al. (2008) Treatment of trochanteric fractures with the PFNA (proximal femoral nail antirotation) nail system – report of early results Bull NYU Hosp Jt Dis 66:276-279.
12. Muller ME, Nazarian S (1981) Classification of fractures of the femur and its use in the A.O. index (author's transl) Rev Chir Orthop Reparatrice Appar Mot 67:297-309.
13. Parker MJ, Palmer CR (1993) A new mobility score for predicting mortality after hip fracture J Bone Joint Surg Br 75:797-798.
14. Jones HW, Johnston P, Parker M (2006) Are short femoral nails superior to the sliding hip screw? A meta-analysis of 24 studies involving 3,279 fractures Int Orthop 30:69-78.
15. Geiger F, Zimmermann-Stenzel M, Heisel C, Lehner B, Daecke W (2007) Trochanteric fractures in the elderly: the influence of primary hip arthroplasty on 1-year mortality Arch Orthop Trauma Surg 127:959-966.
16. Giraud B, Dehoux E, Jovenin N, Madi K, Harisboure A, et al. (2005) Pertrochanteric fractures: a randomized prospective study comparing dynamic screw plate and intramedullary fixation Rev Chir Orthop Reparatrice Appar Mot 91:732-736.
17. Pajarinen J, Lindahl J, Michelsson O, Savolainen V, Hirvensalo

- E (2005) Pertrochanteric femoral fractures treated with a dynamic hip screw or a proximal femoral nail. A randomised study comparing post-operative rehabilitation J Bone Joint Surg Br 87:76-81.
18. Saudan M, Lubbeke A, Sadowski C, Riand N, Stern R, Hoffmeyer P (2002) Pertrochanteric fractures: is there an advantage to an intramedullary nail? A randomized, prospective study of 206 patients comparing the dynamic hip screw and proximal femoral nail J Orthop Trauma 16:386-393.
  19. Foulongne E, Gilleron M, Roussignol X, Lenoble E, Dujardin F (2009) Mini-invasive nail versus DHS to fix pertrochanteric fractures: a case-control study Orthop Traumatol Surg Res 95:592-598.
  20. Radford PJ, Needoff M, Webb JK (1993) A prospective randomised comparison of the dynamic hip screw and the gamma locking nail J Bone Joint Surg Br 75:789-793.
  21. Kaiser W, Burmester J, Hausmann H, Gulielmos V, Hatzel M, Merker HJ (1997) Comparative stability evaluation of dynamic hip screw and gamma-nail osteosyntheses in unstable pertrochanteric femoral osteotomies Langenbecks Arch Chir 382:100-106.
  22. Haynes RC, Poll RG, Miles AW, Weston RB (1997) Failure of femoral head fixation: a cadaveric analysis of lag screw cut-out with the gamma locking nail and AO dynamic hip screw Injury 28:337-341.
  23. Utrilla AL, Reig JS, Munoz FM, Tufanisco CB (2005) Trochanteric gamma nail and compression hip screw for trochanteric fractures: a randomized, prospective, comparative study in 210 elderly patients with a new design of the gamma nail J Orthop Trauma 19:229-233.
  24. Rethnam U, Cordell-Smith J, Kumar TM, Sinha A (2007) Complex proximal femoral fractures in the elderly managed by reconstruction nailing -complications & outcomes: a retrospective analysis J Trauma Manag Outc
  25. Valverde JA, Alonso MG, Porro JG, Rueda D, Larrauri PM, Soler JJ (1998) Use of the gamma nail in the treatment of fractures of the proximal femur Clin Orthop Relat Res 356-61.
  26. Larsson S, Friberg S, Hansson LI (1990) Trochanteric fractures. Influence of reduction and implant position on impaction and complications Clin Orthop Relat Res 130-139.
  27. Gadegone WM, Salphale YS (2007) Proximal femoral nail-an analysis of 100 cases of proximal femoral fractures with an average follow up of 1 year Int Orthop 31:403-408.
  28. Leung KS, Chen CM, So WS, Sato K, Lai CH, Machaisavariya B, et al. (1996) Multicenter trial of modified gamma nail in East Asia Clin Orthop Relat Res 146-154.
  29. Goldhagen PR, O'Connor DR, Schwarze D, Schwartz E (1994) A prospective comparative study of the compression hip screw and the gamma nail J Orthop Trauma 8:367-372.
  30. Tigani D, Laus M, Bettelli G, Boriani S, Giunti A (1992) The gamma nail, sliding-compression plate. A comparison between the long-term results obtained in two similar series Chir Organi Mov 77:151-158.
  31. Thomas AP (1991) Dynamic hip screws that fail Injury 22:45-46.
  32. Chan KC, Gill GS (2000) Cemented hemiarthroplasties for elderly patients with intertrochanteric fractures Clin Orthop Relat Res 206-215.
  33. Sadowski C, Lubbeke A, Saudan M, Riand N, Stern R, Hoffmeyer P (2002) Treatment of reverse oblique and transverse intertrochanteric fractures with use of an intramedullary nail or a 95 degrees screw-plate: a prospective, randomized study J Bone Joint Surg Am 84-A:372-381.
  34. Waast D, Touraine D, Wessely L, Ropars M, Coipeau P, et al. (2007) Pertrochanteric fractures in elderly subjects aged over 75 Rev Chir Orthop Reparatrice Appar Mot 93:2S33-46S.
  35. Brunner A, Jockel JA, Babst R (2008) The PFNA proximal femur nail in treatment of unstable proximal femur fractures -3 cases of postoperative perforation of the helical blade into the hip joint J Orthop Trauma 22:731-73
  36. Mereddy P, Kamath S, Ramakrishnan M, Malik H, Donnachie N (2009) The AO/ASIF proximal femoral nail antirotation (PFNA): a new design for the treatment of unstable proximal femoral fractures Injury 40:428-432.
  37. Suckel AA, Dietz K, Wuelker N, Helwig P (2007) Evaluation of complications of three different types of proximal extra-articular femur fractures: differences in complications, age, sex and surviving rates Int Orthop 31:689-69
  38. Xu YZ, Geng DC, Mao HQ, Zhu XS, Yang HL (2010) A comparison of the proximal femoral nail antirotation device and dynamic hip screw in the treatment of unstable pertrochanteric fracture J Int Med Res 38:1266-127
  39. Zou J, Xu Y, Yang H (2009) A comparison of proximal femoral nail antirotation and dynamic hip screw devices in trochanteric fractures J Int Med Res 37:1057-1064.
  40. Garg B, Marimuthu K, Kumar V, Malhotra R, Kotwal PP (2011) Outcome of short proximal femoral nail antirotation and dynamic hip screw for fixation of unstable trochanteric fractures. A randomised prospective comparative trial Hip Int 21:531-536.
  41. Liu Y, Tao R, Liu F, Wang Y, Zhou Z, Cao Y, et al. (2010) Mid-term outcomes after intramedullary fixation of peritrochanteric femoral fractures using the new proximal femoral nail antirotation (PFNA) Injury 41:810-817.
  42. Xu Y, Geng D, Yang H, Wang X, Zhu G (2010) Treatment of unstable proximal femoral fractures: comparison of the proximal femoral nail antirotation and gamma nail 3 Orthopedics 33:473.
  43. Yaozeng X, Dechun G, Huilin Y, Guangming Z, Xianbin W (2010) Comparative study of trochanteric fracture treated with the proximal femoral nail anti-rotation and the third generation of gamma nail Injury 41:1234-1238.

**Copyright:** ©2022: Saccomanni Bernardino. This is an open-access article distributed under the terms of the Creative Commons Attribution License, which permits unrestricted use, distribution, and reproduction in any medium, provided the original author and source are credited.