



www.medclinres.org

MEDICAL & CLINICAL RESEARCH

Unicornuate Uterus with Non-Communicating Non-Cavitated Rudimentary Uterine Horn: An Unusual Case with Adenomyosis Managed with Total Hysterectomy

Ahmed Samy El-Agwany* and Tamer Abdeldayem

*Corresponding author:

Ahmed S El-agwany, Shatby Maternity University Hospital, Department of Obstetrics and Gynecology, Faculty of Medicine, Alexandria University, Alexandria, Egypt, Tel: 00201228254247

✉ ahmedsamyagwany@gmail.com

Department of Obstetrics and Gynecology, Faculty of Medicine, Alexandria University, Egypt

Received: September 9, 2015; **Accepted:** September 14, 2015; **Published:** September 20, 2015

Abstract

A 45-year-old woman admitted to our hospital complaining of perimenopausal uterine bleeding not responding to medical treatment. Ultrasound evaluation revealed unicornuate uterus with adenomyosis and it was so difficult to see the distant small left rudimentary horn on ultrasound. The patient underwent laparotomy with total hysterectomy for both horns and was sent to pathologist that indicated adenomyosis and non-communicating non-cavitated left rudimentary horn.

Introduction

Unicornuate uterus is a rare congenital anomaly (2%–10% of all types of uterovaginal anomalies which occurs in 2 % of population) [1] in which the partial development of one Mullerian duct results in various degrees of rudimentary horns connected or not to the other horn. According to Buttram Jr. and Gibbons classification [2], the presence of a rudimentary cavity horn, Non-communicating with the other one, represents the A1b variant by class II of the unicornuate uterus.

We present a case of unicornuate uterus with rudimentary horn that was successfully treated by hysterectomy for adenomyosis with persistent vaginal bleeding.

Case Report

A 45-year-old female referred to our department with persistent perimenopausal uterine bleeding not responding to medical treatment inform of progesterone and haemostatics since months. She had three children with history of vaginal delivery and no previous laparotomies. Ultrasound (2D and 3D views) showed a unicornuate uterus with adenomyotic features with failure to visualize the other horn with both adnexa seen ,and both kidneys appeared normal (Figure 1,2).

The patient was not informed about that before weather on delivery or other ultrasound examinations. Under general anaesthesia, the patient underwent laparotomy for hysterectomy that revealed unicornuate uterus, but it was very unusual to see a completely separated and distant left horn, with non-communication and non-cavitated, with both adnexa attached to the both horns (Figure 3).

A rectovesical band was seen between both horns that might be the aetiology for the non-union of the 2 Mullerian ducts. Excision of this band was performed by scissors before starting the hysterectomy (Figure 4).

Hysterectomy was performed in the usual technique. Total hysterectomy with bilateral salpingo-oophorectomy was done and the specimen was sent for histopathology that confirmed adenomyosis in the right horn and non-communicating non-cavitated left rudimentary horn.

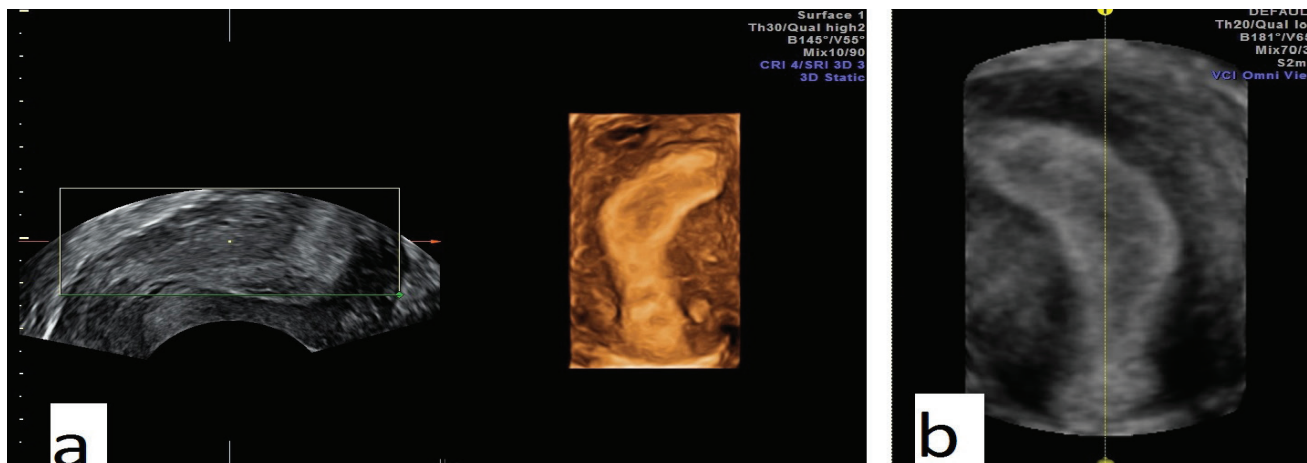


Figure 1: 2D and 3D ultrasound view showing unicornuate uterus

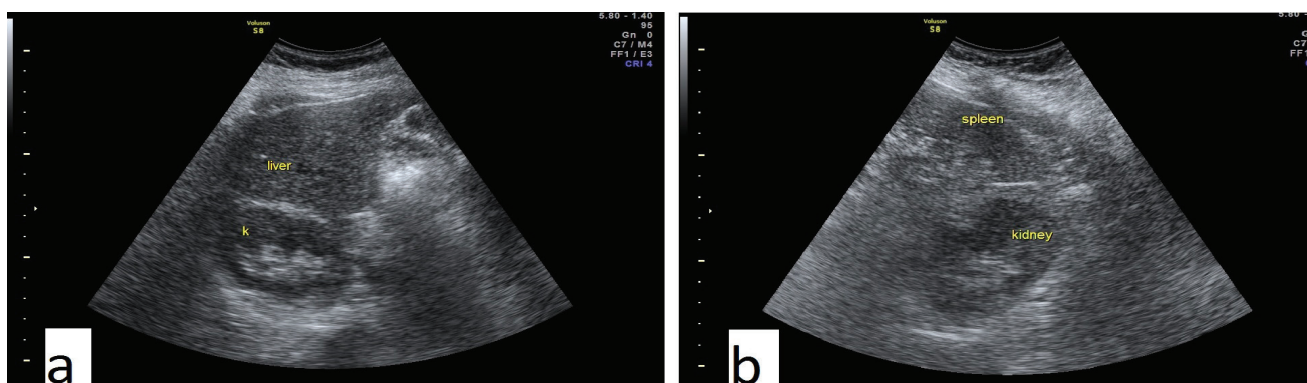


Figure 2: 2D ultrasound showing normal both kidneys

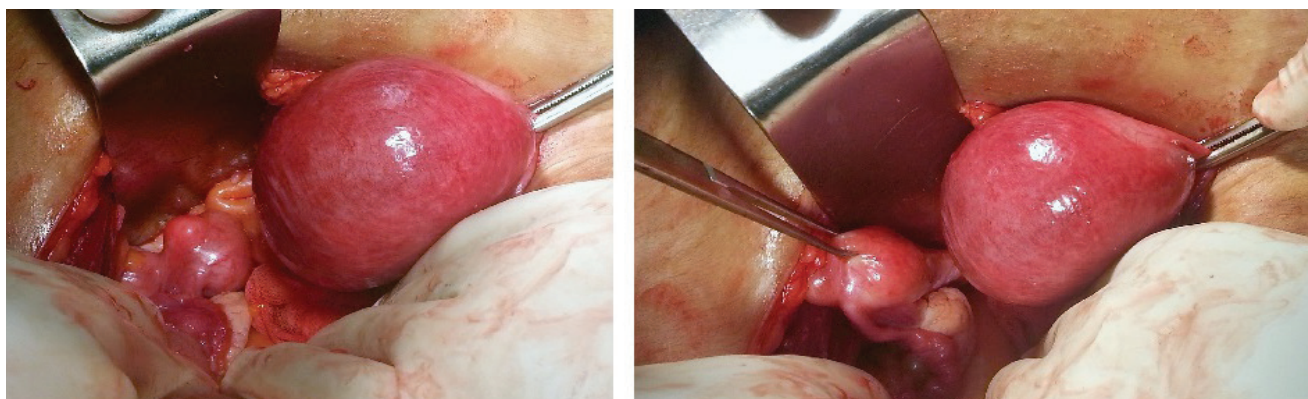


Figure 3: Operative view showing unicornuate uterus with rudimentary left horn with adnexa attached to both horns

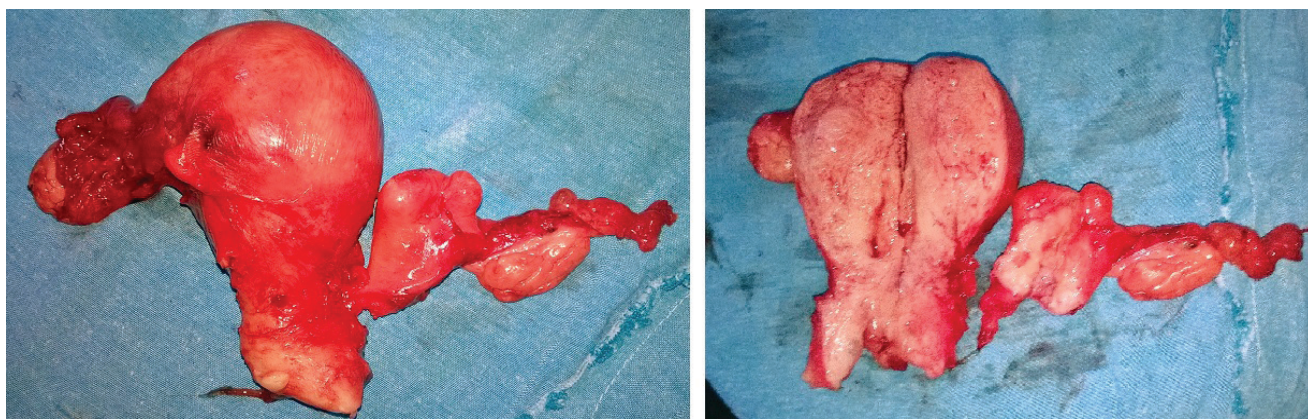


Figure 4: Hysterectomy specimen showing total hysterectomy with bilateral salpingo-oophorectomy with unicornuate uterus with rudimentary non communicating non cavitated left horn

Discussion

The frequency of A1b variant by class II of the unicornuate uterus classified by Buttram Jr. and Gibbons is 7.7%–42.9% of all unicornuate uterus with a rudimentary horn [3,4]. The association with pregnancy complications is not mandatory, as shown by the obstetric history of our patient, other complications are infertility, abortion and preterm labour. Gynaecological conditions associated are dysmenorrhea (estimated in 70% of cases), hematometra (in 50%), and endometriosis (in 20%-40% of cases) [5]. The diagnosis of unicornuate uterus is not so easy sometimes, and it can even be missed by inexperienced surgeons and sonographers. Proper identification and diagnosis of mullerian anomaly, however, is critical to assess the right surgical approach, because the procedure is greatly influenced by the specific subtype and by anatomical characteristics of the uterus, such as the extent of the connection between the rudimentary horn and the unicornuate uterus [6-9].

As previously described by Fedele et al. [3], the unicornuate uterus with rudimentary horn brings itself some intrinsic variations of the classic pelvic anatomy: frequently, the ureter lateral to the rudimentary horn has a higher course, as it lies adjacent to the vascular pedicle of the horn. For this reason, it should be mandatory to identify the ureter course firstly when the round ligament is transected and the broad ligament and retroperitoneal space are entered. Moreover, it has been suggested [7] to perform omolateral salpingectomy as the last surgical step, rather than excising it at the same time of the uterine horn.

Conclusion

In managing challenging rare cases of anomalies, such as the one affecting our patient, surgeon skills and decisions are very important. Operative laparoscopy, ultrasound and MRI are useful in diagnoses although ultrasound may miss the rudimentary horn. The surgical procedure can be complicated by anatomical variations especially in ureter's course.

References

1. Fenton AN, Singh BP (1952) Pregnancy associated with congenital abnormalities of the female reproductive tract. *The American Journal of Obstetrics and Gynecology* 63: 744–755.
2. Buttram Jr VC, Gibbons WE (1979) Mullerian anomalies: a proposed classification (an analysis of 144 cases). *Fertility and Sterility* 32: 40–46.
3. Elagwany AS (2013) Ruptured ectopic pregnancy in non-communicating right rudimentary horn: A case report. *Apollo Medicine*.
4. Donderwinkel PF, D'orr JP, Willemsen WN (1992) The unicornuate uterus: clinical implications," *European Journal of Obstetrics and Gynecology and Reproductive Biology* 47: 135–139.
5. P.K. Heinonen (1997) Unicornuate uterus and rudimentary horn. *Fertility and Sterility* 68: 224–239.
6. Fedele L, Bianchi S, Zanconato G, Berlanda N, Bergamini V (2005) Laparoscopic removal of the cavitated noncommunicating rudimentary uterine horn: surgical aspects in 10 cases. *Fertility and Sterility* 83: 432-436.
7. Michele Morelli, Roberta Venturella, Rita Mocchiari, Daniela Lico, and Fulvio Zullo (2013) An Unusual Extremely Distant Noncommunicating Uterine Horn with Myoma and Adenomyosis Treated with Laparoscopic Hemihysterectomy. *Case Reports in Obstetrics and Gynecology*.
8. Chakravarti S, Chin K (2003) Rudimentary uterine horn: management of a diagnostic enigma. *Acta Obstet Gynecol Scand* 82: 1153-1154.
9. Stitely ML, Hopkins K (2006) Laparoscopic removal of a rudimentary uterine horn in a previously hysterectomized patient. *JSLs* 10: 257-258.

Citation:

Ahmed Samy El-Agwany and Tamer Abdeldayem Unicornuate (2015) Uterus with Non-Communicating Non-Cavitated Rudimentary Uterine Horn: An Unusual Case with Adenomyosis Managed with Total Hysterectomy. *Med Clin Res* 1: 1-3.